

RESENTING CLINICAL SIGNS

History: Hx of degenerative valve disease. Doing well.

DATE

12/24/21 **ECHOCARDIOGRAPHIC FINDINGS**
2D, M-mode, and Doppler study.

PERFORMED BY: Left atrial size is normal. The mitral valve leaflets are mildly thickened, and a mild jet of mitral regurgitation is present. Left ventricular dimensions are normal. Left ventricular systolic function is normal. The aorta and aortic valve are normal. Right atrial and right ventricular dimensions are normal. The tricuspid valve leaflets are mildly thickened, and a mild jet of tricuspid regurgitation is present. TR velocity does not suggest the presence of pulmonary hypertension. The pulmonary artery and pulmonic valve are normal. No shunting lesions are visualized. No pericardial effusion or cardiac masses are seen.

Shari Reffi, CVT

INTERPRETED BY

Keith Blass, DVM,
MS, DACVIM
(Cardiology)

PATIENT

Papi LaRose

LA - 32.4 mm
LVIDd - 33.4 mm
LVIDs - 21.9 mm
FS - 34.4%
LVOT - 1.00 m/s
RVOT - 1.02 m/s
TR - 2.16 m/s

ASSESSMENT/RECOMMENDATIONS

Degenerative mitral and tricuspid valve disease

SPECIES

Canine

This examination again demonstrates mild regurgitation of blood across Papi's mitral and tricuspid valves resulting from degenerative valve disease. The hemodynamic effects of each of the regurgitations still appear to be mild, as Papi again does not have secondary dilation of any of his cardiac chambers. As such, Papi's valvular diseases appear to be well-compensated, and his current risk for the development of clinical signs secondary to them appears to be low.

BREED

Shepherd Mix

No therapy is recommended at this stage of disease.

SEX

A recheck echocardiogram is recommended in ~6 months to monitor for disease progression.

MN

AGE

7 y

WEIGHT

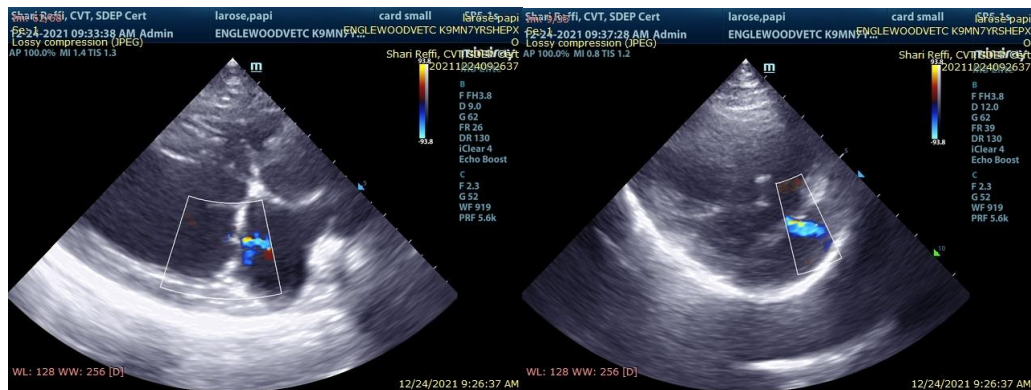
43.4 lb

HOSPITAL NAME

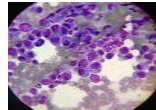
Englewood VC

REFERRING VET

Dr. Ezik



The information and recommendations provided are based on the images presented by the referring veterinarian. No evaluation can be communicated regarding pathology that was not visible in the image/video clips provided.



Thank you for this referral. If the clinical or image interpretation does not parallel your findings or if I can be of any further assistance please contact me.

DATE

12/24/21

Keith Blass, DVM, MS, DACVIM (Cardiology)
KeithBlass@gmail.com
631-804-5754

PERFORMED BY:

Shari Reffi, CVT

INTERPRETED BY

Keith Blass, DVM,
MS, DACVIM
(Cardiology)

PATIENT

Papi LaRose

SPECIES

Canine

BREED

Shepherd Mix

SEX

MN

AGE

7 y

WEIGHT

43.4 lb

HOSPITAL NAME

Englewood VC

REFERRING VET

Dr. Ezik